

Diagnosis

Early, mild androgenetic alopecia; Sinclair Hair Score 1.25

Measurements

Measurements	Value	Date	Notes
Anterior Crown	160	2/20/2X	
Left outer canthus (outside eye) to sideburn	4cm	2/20/2X	
Left outer canthus (outside eye) to temporal hairline	5cm	2/20/2X	
Glabella to hairline	6cm	2/20/2X	
Right outer canthus (outside eye) to temporal hairline	4cm	2/20/2X	
Right outer canthus (outside eye) to sideburn	5cm	2/20/2X	

Treatment Recommendations

Minoxidil 2% solution for women

Spironolacton 150mg by mouth daily

Tasks

Repeat ScalpSurvey in 3 months after initiation of minoxidil

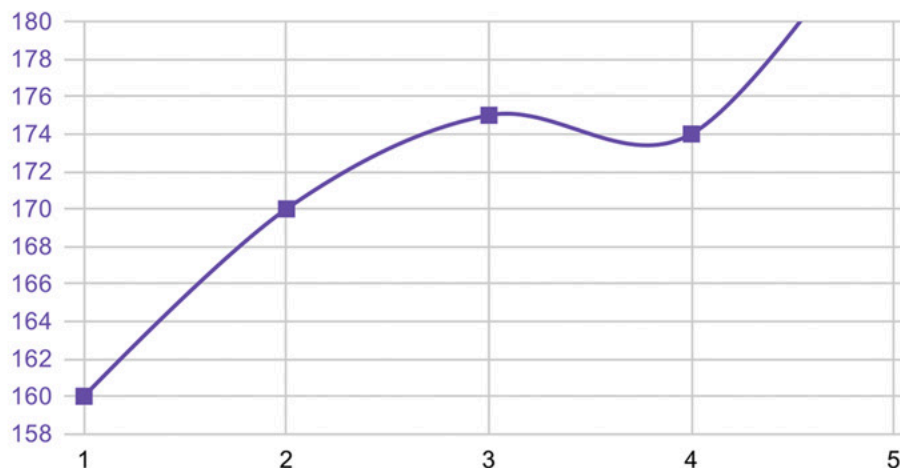
Repeat blood test in 2 months

Avoid foods heavy in potassium

	Field 1	Field 2	Field 3
# of hair in green circle	70	71	70
Multiplier	2.27	2.27	2.27
Density of Hairs / cm2	159	161	159

Let's grow together! Please send any questions to contact@pilaris.com

Hair Density Plot

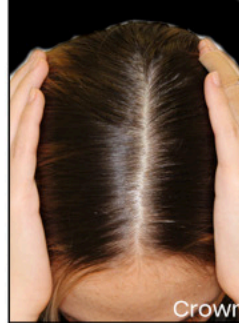
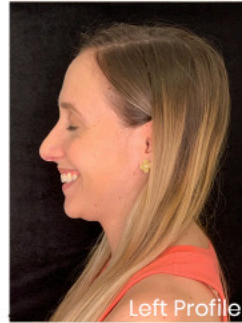
Patient: Amanda Eisinger Date: 02/28/2X

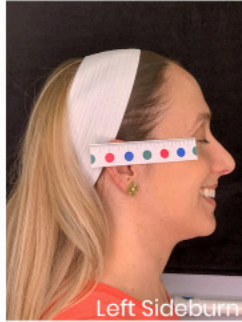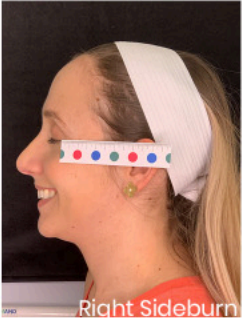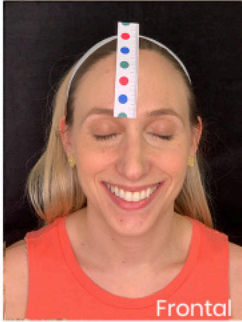Gender: Female

Analyst: Dr. Kumar Sukhdeo

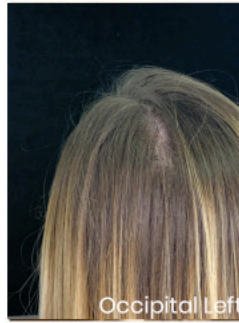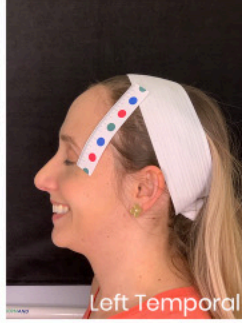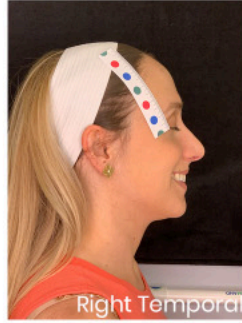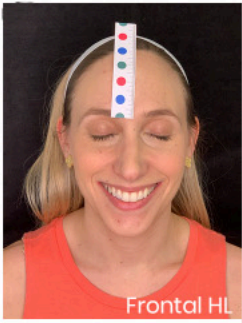Cell Phone Photos



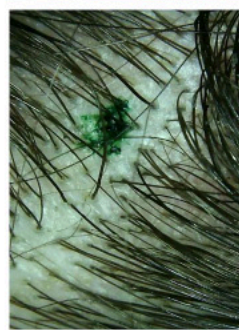
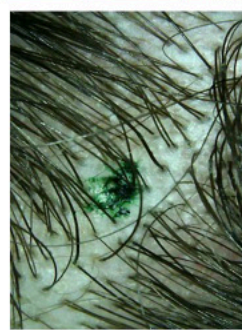
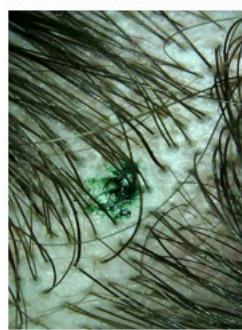
Cell Phone Photos






Cell Phone Photos



ScalpScope Photos



ScalpScope Photos



Analyst Comments

Hairline preserved
 Eyebrows, eyelashes intact
 No facial papules (normal)
 No evidence of hypertrichosis (normal)
 No evidence of hirsutism (normal)
 Widened mid-line part
 Decreased density on crown & vertex

Hairline preserved
 See attached report for measurements
 *HL = hairline

Field Analysis (12cm from glabella):
 Analytic Field Size: 0.44cm²
 Converted Hair Density: 160 hairs/cm²
 Reference Hair Density: 180ttv-220/cm²
 Scalp: No scarring, erythema
 No perifollicular scaling
 No hair shaft abnormalities
 Increased % of minaturized hairs